

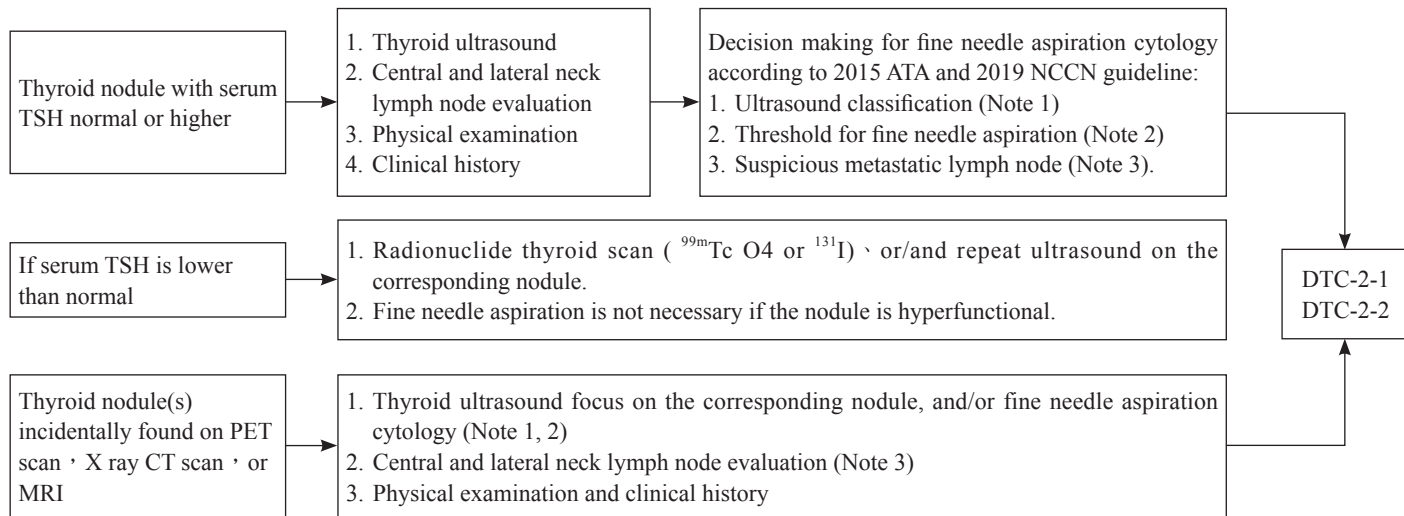
The background features a light gray gradient with several overlapping geometric shapes. A large, light gray diamond is centered, with a smaller, darker gray diamond to its left. A white diamond is also present, overlapping the light gray one. In the corners, there are faint, semi-transparent circles. The text 'Thyroid Cancer' is centered within the white diamond, underlined.

Thyroid Cancer

《Taipei Medical University Hospital Management guideline for Differentiated Thyroid Cancer; DTC-1》

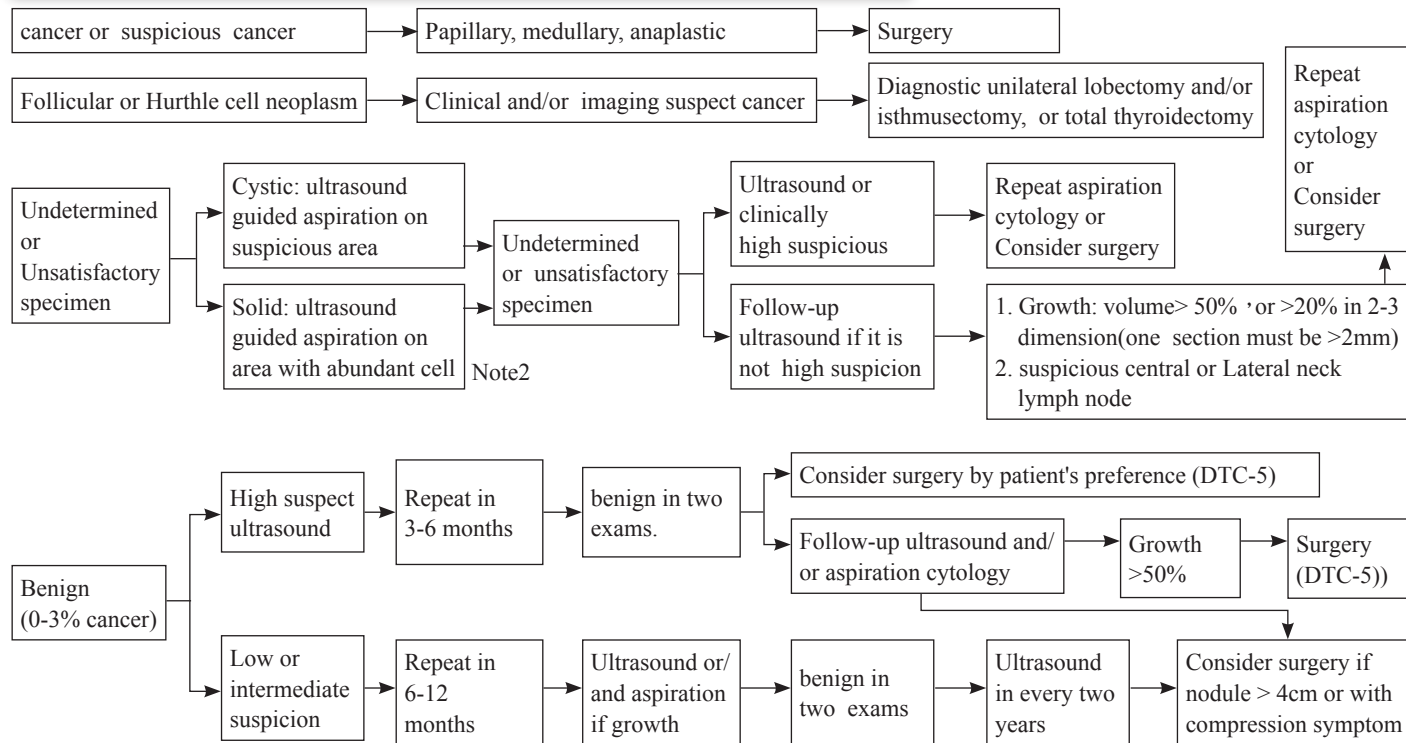
Management guideline of differentiated thyroid cancer DTC-1

Evaluate thyroid nodule(s) – 1

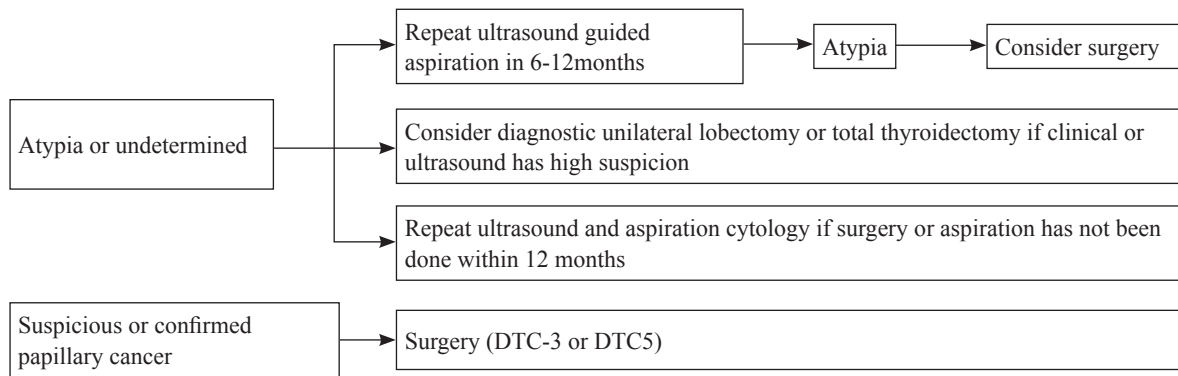


《 Management guideline of differentiated thyroid cancer DTC-2-1 》

Evaluate thyroid nodule(s) – 2 : result of fine needle aspiration cytology

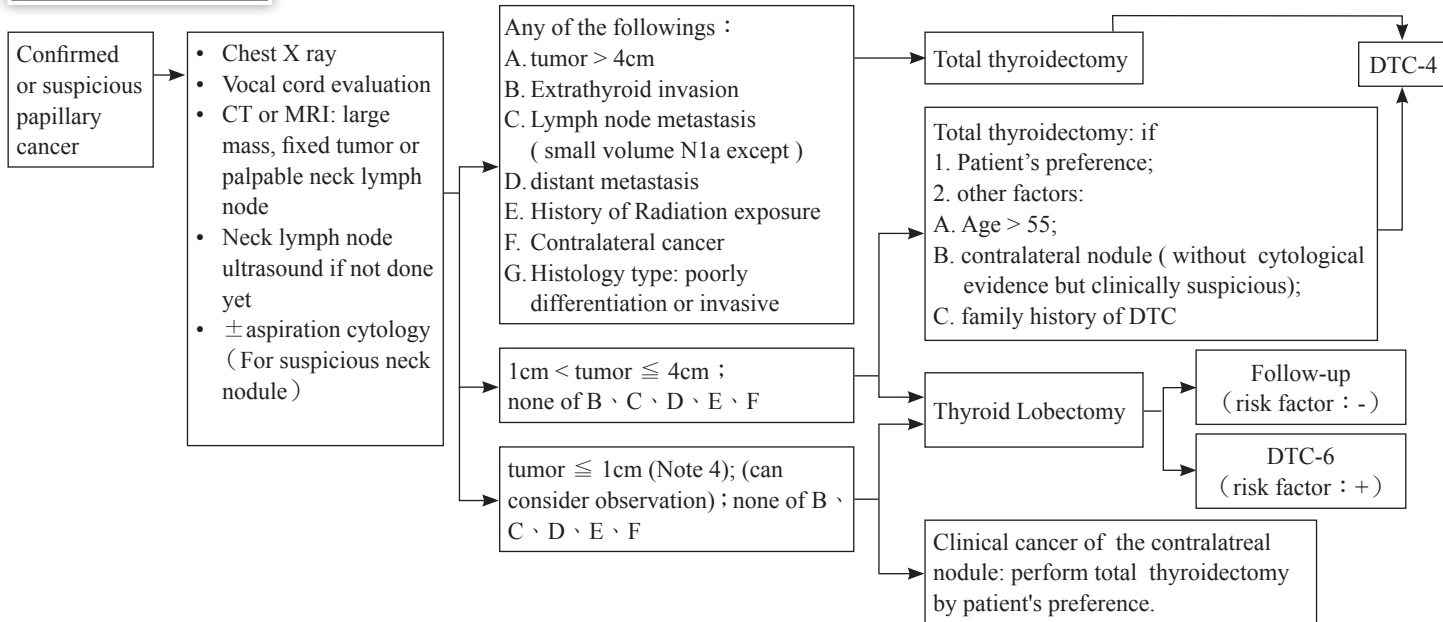


Evaluate thyroid nodule(s) – 2 : result of fine needle aspiration cytology based on Bethesda system (continue)



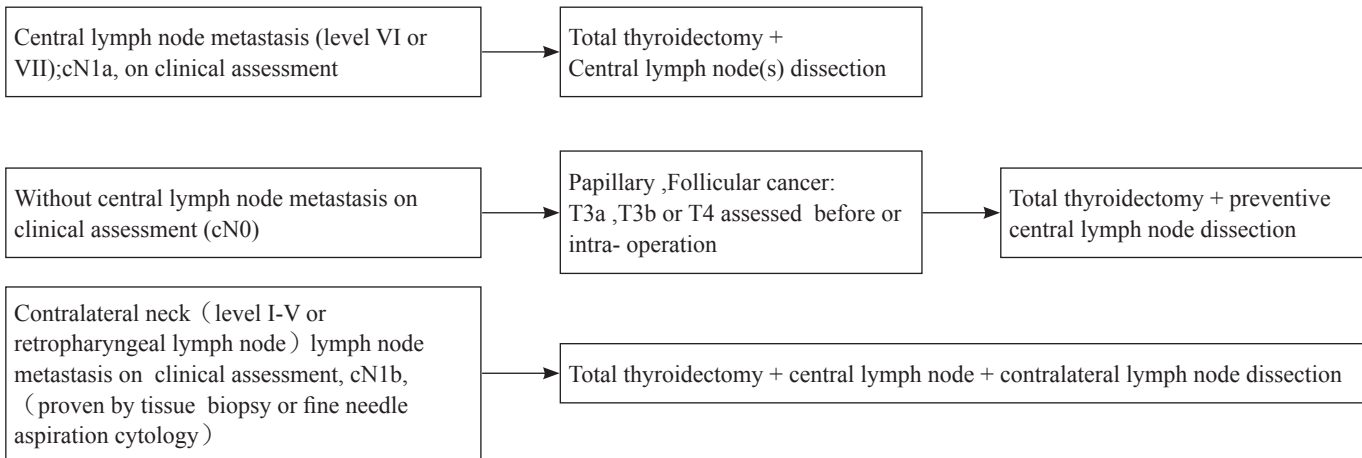
《 Management guideline of differentiated thyroid cancer **DTC-3** 》

Initial operation – 1



- small volume N1a meta : <5 involved nodes with no meta > 2mm in largest dimension
- Completion thyroidectomy is not required for small volume N1a meta (<5 involved nodes with no meta > 5mm in largest dimension)

Initial operation – 2 (lymph node dissection)



《 Management guideline of differentiated thyroid cancer **DTC-5** 》

Initial operation – 3

1. Aspiration cytology revealed “suspicious”
2. Patient choose operation when cytology revealed “atypia”
3. Patient choose operation when cytology is benign or “undetermined ” on two subsequent exam., while ultrasound shows high suspicion.

Unilateral lobectomy + isthmusectomy + pathological finding on frozen section

Malignancy

Suggest total thyroidectomy and/or lymph node dissection or remains unilateral lobectomy (DTC-3)

DTC-4

Malignancy hasn't been determined on frozen section, but intra- or post-operative pathology revealed strap muscle invasion lymphovascular invasion, poor differentiation of cell, or central lymph node metastasis

Decision making based on DTC-6:
If total thyroidectomy is necessary

Follicular neoplasm or follicular lesion with undetermined significance

Lobectomy /isthemectomy

invasive

Total thyroidectomy

Minimal invasive

Total thyroidectomy or Active velliance

《 [Differentiated Thyroid Cancer; DTC] DTC-6 》

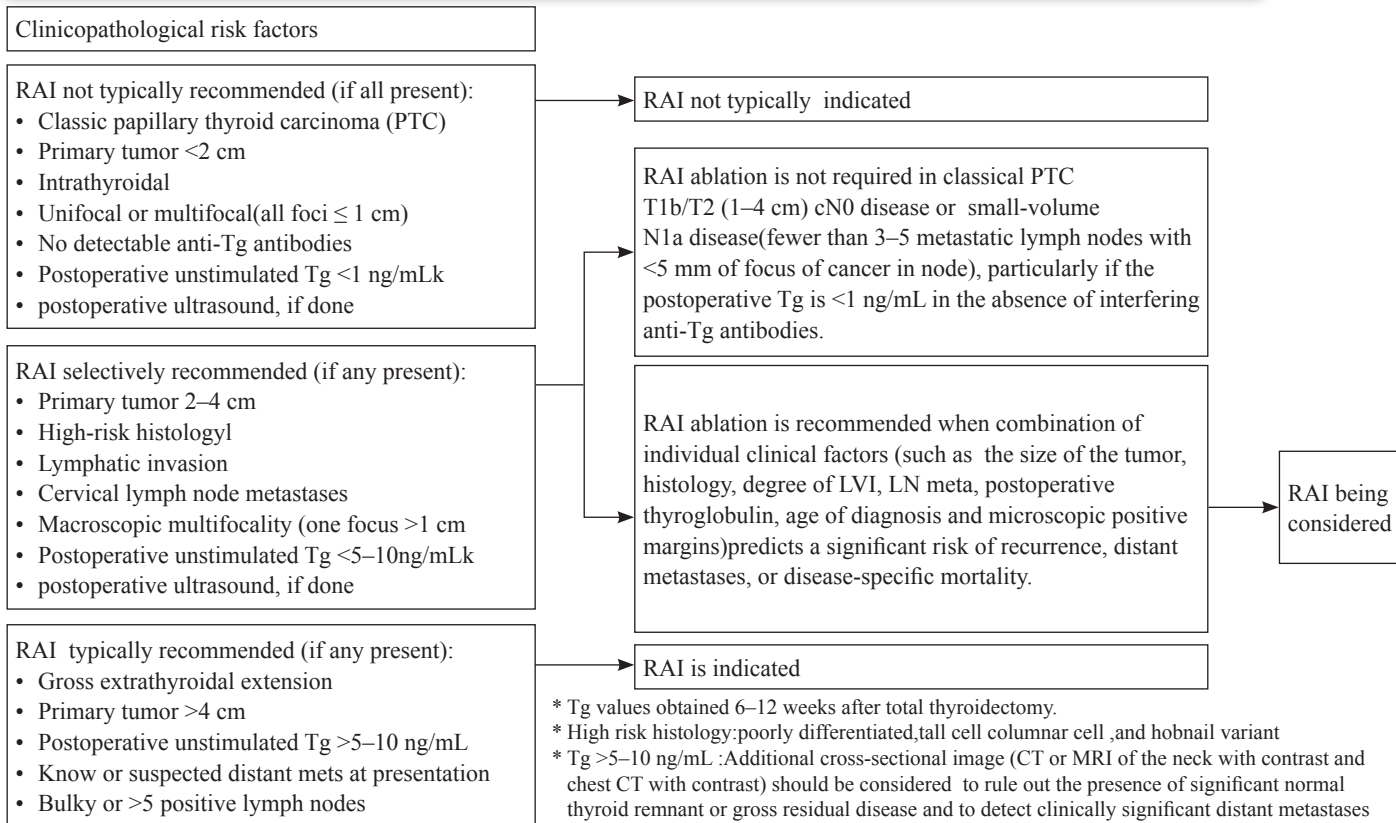
CLINICAL PRESENTATION			PRIMARY TREATMENT	
Papillary carcinoma found post- lobectomy	<ul style="list-style-type: none"> • Thyroid and neck ultrasound(including central and lateral compartments), if not previously done • Biopsy suspicious lymph nodes or contralateral lesions 	Any of the following: <ul style="list-style-type: none"> • Tumor >4 cm • Gross positive resection margins(R1orR2) • Gross extra-thyroidal extension • Macroscopic multifocal disease (>1 cm) • Confirmed nodal metastasisg • Confirmed contralateral disease • Vascular invasion • Poorly differentiated 	Completion of thyroidectomy	<ul style="list-style-type: none"> • Perform therapeutic neck dissection of involved compartments for clinically apparent/ biopsy-proven disease
		<ul style="list-style-type: none"> • Tumor 1–4 cm in diameter or • Lymphatic invasion 	Completion of thyroidectomy	
			Or Disease monitoringk (category 2B)	Consider levothyroxine therapy to keep TSH low or normal
		All of the following: <ul style="list-style-type: none"> • Negative resection margins(R0) • No contralateral lesion • Tumor <1 cm in diameter • No suspicious lymph node or • NIFTPh 	Disease monitoringk	Consider levothyroxine therapy to keep TSH low or normal

註 1 Completion of thyroidectomy is not required for incidental small volume pathologic N1A metastases (<5 involved nodes with no metastasis >2 mm in largest dimension).

註 2 Formerly called encapsulated follicular variant of PTC, noninvasive follicular thyroid neoplasm with papillary-like nuclear features (NIFTP) has been reclassified and only lobectomy is needed. Ongoing surveillance is recommended.

《([Medullary Carcinoma Thyroid Cancer;]) -7》

CLINICAL PRESENTATION	DIAGNOSTIC PROCEDURES		PRIMARY TREATMENT
Medullary thyroid carcinoma on FNA	<ul style="list-style-type: none"> • Basal serum calcitonin level • CEA • Pheochromocytoma screening^b • Serum calcium • Consider genetic counseling • Screen for germline <i>RET</i> proto-oncogene mutations^c (exons 10, 11, 13–16) • Thyroid and neck ultrasound (including central and lateral compartments), if not previously done • Consider evaluation of vocal cord mobility (ultrasound, mirror indirect laryngoscopy, or fiberoptic laryngoscopy)^d 	≥ 1.0 cm in diameter or bilateral thyroid disease	<ul style="list-style-type: none"> • Total thyroidectomy with bilateral central neck dissection (level VI) • Therapeutic ipsilateral or bilateral modified neck dissection for clinically or radiologically identifiable disease (levels II–V) • Consider prophylactic ipsilateral modified neck dissection for high-volume or gross disease in the adjacent central neck • For positive margins (R1 or R2), consider therapeutic radiotherapy • Postoperative administration of levothyroxine to normalize TSH
	<ul style="list-style-type: none"> • Additional cross-sectional imaging as indicated:^f <ul style="list-style-type: none"> ➤ Consider contrast-enhanced CT of neck/ chest and liver MRI or 3-phase CT of liver,^{e,f} ➤ Consider Ga-68 DOTATATE PET/CT; if not available consider bone scan and/or skeletal MRI 	<1.0 cm in diameter and unilateral thyroid disease	Total thyroidectomy and consider neck dissection (level VI)



《 Management guideline of differentiated thyroid cancer **DTC-8** 》

I-131 treatment after total or near total thyroidectomy

Based on pathology/operative finding/post-operative serum thyroglobulin (Tg) level at 4-6 weeks/ Tc-99m O4 or I-131 scan/neck ultrasound

Tumor size (T)	AJCC staging	Recurrent risk (Note 5)	Remarks	I-131 treatment /dose
T ≤ 2cm	T1, N0/Nx, M0/Mx	Low	Typical papillary 、 single (pT1) or multiple (mpT1) lesions confined in thyroid 、 unstimulated Tg <1 ng/mL+ TgAb –	low dose I131 treatment / consider patient performance and Combined Meeting decide
2 < T ≤ 4cm	T2,N0/Nx, M0/Mx	Low	not routine ; RAI maybe considered for Whether there is a more malignant tissue; vascular or lymphatic invasion	May consider low/high doses 30 m Ci/100-150 mCi
T > 4cm	T3, N0/Nx, M0/Mx	Low to high	Consider unfavorable clinical features 、 lymphovascular invasion or extrathyroid extension 、 microscopic extranodal extension 、 unstimulated serum Tg>5-10 ng/mL+ 、 macroscopic multifocality (one focus >1cm) 、 age >55	Usually consider high/low dose 100-150 mCi/30 mCi
Any T1-3	T3, N0/Nx, M0/Mx	Low to high	Gross Extension to strap muscles	suggest high/ low dose
AnyT1-3	T1-3, N1a(Note3), M0/Mx	Low to Intermediate	Central lymph node metastasis (Note 3). Consider the number and size of metastatic lymph node or ENE(+), maybe unnecessary or give small dose as <5# and each <5mm if no unfavorable clinical feature or age>55	suggest high/ low dose
Any T1-3	T1-3, N1b, M0/Mx	Low to Intermediate	Lateral or retropharyngeal lymph node metastasis	suggest high dose
Any size	T4, any N, any M	High	Gross tumor extrathyroid invasion 、 suspect distant metastasis via imaging	Necessary / high dose ≥ 150 mCi
Any size	M1, any T, any N	High	1.distant metastasis or I-131 、 CT scan suspect distant metastasis 2.postoperative serum Tg > 5-10 ng/ml	Necessary / high dose ≥ 150 mCi

Note 1. Consider >100 mCi I-131 treatment and perform post-therapy whole body scan if post-therapy stimulated Tg >10 ng/mL or progressive elevation of Tg during the follow-up period, even imaging diagnoses are negative.

2. Central regional lymphatic metastasis ≤ 5 and < 0.2cm and no other negative characteristics

3. Central regional lymphatic metastasis > 5 or ≥ 0.2cm or other unfavorable features (microscopic extranodal extension)

《 Management guideline of differentiated thyroid cancer DTC-9 》

Evaluate therapeutic effect after initial treatment/6-12 months after operation/I-131 treatment

Suggestion of afterward management

Evaluation of complete therapy: 1. Physical examination 2. Measurement of serum TSH, thyroglobulin and thyroglobulin antibody every 3-6 months 3. Periodic neck ultrasound 4. Stimulated I-131 whole body scan on the following patient:(1) recurrence high risk(2) I-131 avid lesion detected on the previous study(3) abnormal or persistent elevated serum thyroglobulin or thyroglobulin antibody levels on the previous blood tests

Recurrence Risk(note 5)	Surgical method	Methods for evaluation	Therapeutic response (Note 6) thyroglobulin (Tg; ng/ml)	Management: thyroxin supplement/suppressive (TSH level**; IU/L; normal reference 0.5-5)
Low	Unilateral lobectomy	1.Unstimulated serum Tg 2.Neck ultrasound	Good result: neck ultrasound* Stable unstimulated serum Tg , TgAb- Biochemical or structure result is incomplete or unable to evaluate	TSH 0.5-5.0 (Note 7); unstimulated serum Tg +Neck ultrasound ATA 2015 for detailed (Note 6)
Low	Total thyroidectomy	1.Unstimulated serum Tg 2.Neck ultrasound 3.Consider I-131 scan	Good result: neck ultrasound* Unstimulated serum Tg <2 , TgAb- Biochemical or structure result is incomplete or unable to evaluate	TSH 0.5-2.0 (Note 7); unstimulated serum Tg +Neck ultrasound ATA 2015 for details (Note 6)
Intermediate	Total thyroidectomy	1.Unstimulated or stimulated serum Tg 2.Neck ultrasound 3.Consider I-131 scan	Good result: neck ultrasound* Unstimulated Tg < 1 TgAb- stimulated Tg < 2 TgAb- negative stimulated I-131 scan	TSH 0.5-2.0 (Note7); unstimulated serum Tg +Neck ultrasound+ stimulated I-131 scan
			Biochemical or structure result is incomplete or unable to evaluate	TSH < 0.1 or 0.1-0.5 (only biochemical response is not good), thyroxin withdrawal or rhTSH injection for I-131 scan
High	Total thyroidectomy	1.Unstimulated or stimulated serum Tg 2.Neck ultrasound 3.I-131 scan after stimulation 4.CT, MRI and/or FDG PET#	Good result: neck ultrasound*, unstimulated Tg undetectable(<0.1 或 <0.2) TgAb- stimulated Tg < 1, TgAb-, negative stimulated I-131 scan	TSH 0.1-0.5 (Noted 7) ; unstimulated Tg, neck ultrasound/ CT/MRI/PET#
			Biochemical or structure result is incomplete or unable to evaluate	Continue TSH < 0.1(undetectable) (Note7); thyroxin withdrawal or rhTSH injection for I-131 scan

*neck ultrasound: normal, stable, and/or normal cytology examination

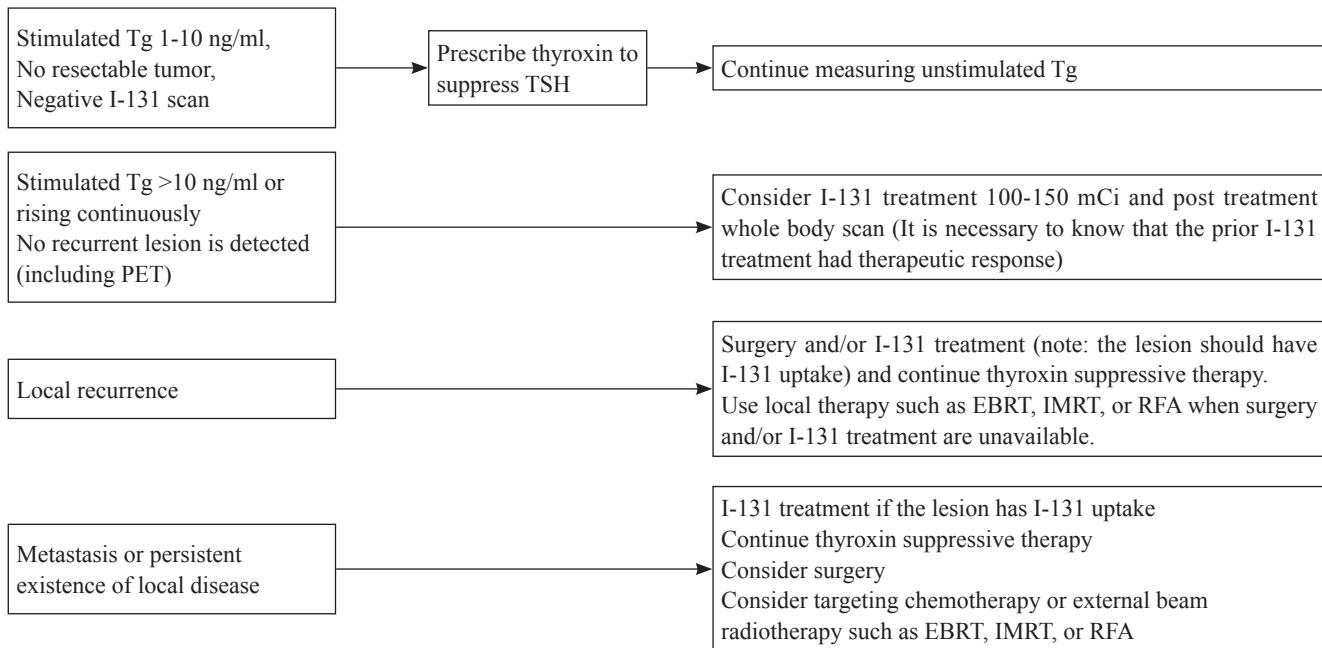
**The risk and benefit of TSH suppression must be balanced for each individual.

Patients whose serum TSH levels are chronically suppressed: daily intake of calcium (1200 mg/d) and Vit. D.

#FDG/PET for positive serum thyroglobulin (Tg) but negative I-131 whole body scan

《 Management guideline of differentiated thyroid cancer DTC-10 》

Follow-up and subsequent treatment



Targeting therapy (Kinase inhibitor; KI) (NCCN 2020)

1. Indications:

Recurrent or persistent tumor, locally advanced or metastatic unresectable medullary thyroid cancer (MTC)

2. Consideration of KI treatment

(1) KI May associate with progressive-free survival, but is not curable

(2) KI expect to cause side effects that may have a significant effect on quality of live

(3) The nature history of DTC and MTC is quite variable with rates of disease progression of a few months to many years.

3. Decision making of treatment:

The pace of disease progression: indolent and asymptomatic or rapid progressive disease

4. Optimal management of side effects are essential (dermatologic, hypertensive and gastrointestinal)- have been fatal.

5. Dose modification maybe required

《 Management guideline of differentiated thyroid cancer DTC-12 》

External Radiotherapy (EBRT)

1. Post operative gross residual disease in neck, which shows inadequate radioiodine uptake for treatment.
2. Unresectable local regional recurrence/persistent disease if radioiodine imaging negative
3. Iodine refractory soft tissue metastases (lung, liver, muscle and CNS)
4. Iodine refractory bone metastases, also consider intravenous bisphosphonate or denosumab and surgery
5. Undifferentiated thyroid cancer

External Beam Radiotherapy (EBRT)*

Differentiated thyroid cancers (Papillary Carcinoma, Follicular carcinoma, Hurthle cell carcinoma)

- Local-regional recurrence or metastasis especially to CNS or bone
 1. Unresectable or unsuitable for surgery
 2. Unsuitable for radioiodine treatment due to radioiodine imaging negative
 3. Progression disease
- May consider adjuvant therapy for high-risk disease after surgery
 1. Microscopic disease after R1
 2. Salvage RT after R2 resection

Medullary carcinoma

1. Unresectable or unsuitable for surgery
2. Locally symptom control

Anaplastic carcinoma+

1. Consider adjuvant RT in R0/R1 resection after total thyroidectomy and lymph node dissection
2. Unresectable or R2 resection after total thyroidectomy and lymph node dissection
3. Palliative for locally symptom control

*, Conformal radiotherapy techniques including intensity-modulated RT are encouraged to reduce toxicity. Proton therapy including intensity-modulated proton therapy could be considered.

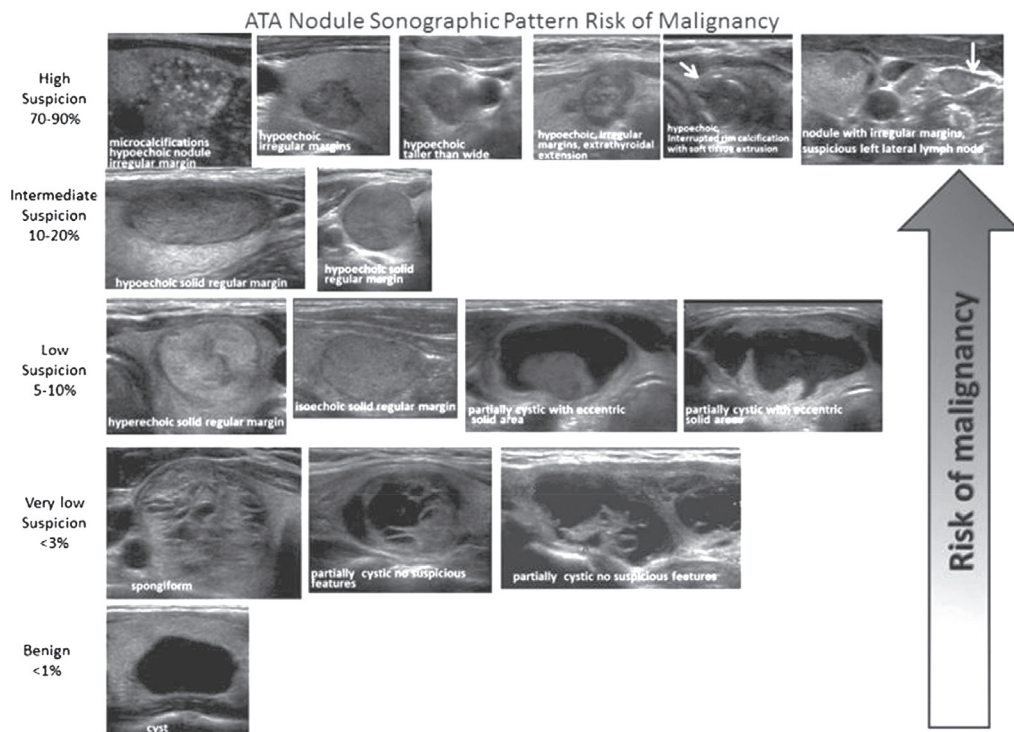
+, For unresected or incompletely resected anaplastic thyroid carcinoma, RT should be started as quickly as possible.

(2015ATA) Stratification of Sonographic Findings According to Probability of malignancy

- **High suspicion [malignancy risk > 70-90%]:** Solid hypoechoic nodule or a solid hypoechoic component in a partially cystic nodule with one or more of the following features: irregular margins (specifically defined as infiltrative, microlobulated, or spiculated), microcalcifications, taller than wide shape, disrupted rim calcifications with small extrusive hypoechoic soft tissue component, or evidence of extrathyroidal extension. A nodule demonstrating this ultrasound pattern is highly likely to be a papillary thyroid cancer.
- **Intermediate suspicion [malignancy risk 10-20%]:** Hypoechoic solid nodule with a smooth regular margin, without microcalcifications, extrathyroidal extension, or taller than wide shape
- **Low suspicion [malignancy risk 5-10%]:** Isoechoic or hyperechoic solid nodule, or partially cystic nodule with eccentric uniformly solid areas without microcalcifications, irregular margin or extrathyroidal extension, or taller than wide shape.
- **Very low suspicion [malignancy risk < 3%]:** Spongiform or partially cystic nodules without any of the sonographic features described in the low, intermediate or high suspicion patterns ; A spongiform appearance is defined as the aggregation of multiple microcystic components in more than 50% of the volume of the nodule
- **Benign [malignancy risk < 1%]:** Purely cystic nodules

《 Management guideline of differentiated thyroid cancer Note 1 continue 1 》

ATA Nodule Sonographic Pattern Risk of Malignancy

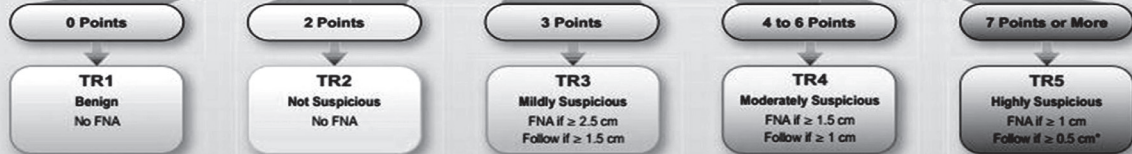

TIRADS (Thyroid imaging reporting and data system)

ACR TI-RADS

COMPOSITION (Choose 1)	ECHOGENICITY (Choose 1)	SHAPE (Choose 1)	MARGIN (Choose 1)	ECHOGENIC FOCI (Choose All That Apply)
Cystic or almost completely cystic 0 points Spongiform 0 points Mixed cystic and solid 1 point Solid or almost completely solid 2 points	Anechoic 0 points Hyperechoic or isoechoic 1 point Hypoechoic 2 points Very hypoechoic 3 points	Wider-than-tall 0 points Taller-than-wide 3 points	Smooth 0 points Ill-defined 0 points Lobulated or irregular 2 points Extra-thyroidal extension 3 points	None or large comet-tail artifacts 0 points Macrocalcifications 1 point Peripheral (rim) calcifications 2 points Punctate echogenic foci 3 points

Add Points From All Categories to Determine TI-RADS Level



COMPOSITION	ECHOGENICITY	SHAPE	MARGIN	ECHOGENIC FOCI
<i>Spongiform</i> : Composed predominantly (>50%) of small cystic spaces. Do not add further points for other categories. <i>Mixed cystic and solid</i> : Assign points for predominant solid component. Assign 2 points if composition cannot be determined because of calcification.	<i>Anechoic</i> : Applies to cystic or almost completely cystic nodules. <i>Hyperechoic/isoechoic/hypoechoic</i> : Compared to adjacent parenchyma. <i>Very hypoechoic</i> : More hypoechoic than strap muscles. Assign 1 point if echogenicity cannot be determined.	<i>Taller-than-wide</i> : Should be assessed on a transverse image with measurements parallel to sound beam for height and perpendicular to sound beam for width. This can usually be assessed by visual inspection.	<i>Lobulated</i> : Protrusions into adjacent tissue. <i>Irregular</i> : Jagged, spiculated, or sharp angles. <i>Extrathyroidal extension</i> : Obvious invasion = malignancy. Assign 0 points if margin cannot be determined.	<i>Large comet-tail artifacts</i> : V-shaped, >1 mm, in cystic components. <i>Macrocalcifications</i> : Cause acoustic shadowing. <i>Peripheral</i> : Complete or incomplete along margin. <i>Punctate echogenic foci</i> : May have small comet-tail artifacts.

*Refer to discussion of papillary microcarcinomas for 5-9 mm TR5 nodules.

《 Management guideline of differentiated thyroid cancer **Note2** 》

Sonographic features and threshold for FNA (NCCN guideline)

Nodule	Threshold for fine needle aspiration (FNA)
Solid nodule with suspicious features [#] without suspicious features	≥ 1.0 cm ≥ 1.5 cm
Mixed cystic-solid nodule with suspicious features without suspicious features	(Cyst: correlate ultrasound and aspirate/re-aspirate suspicious area) Solid component ≥ 1.0 cm Solid component ≥ 1.5 cm
Sponge form nodule *	≥ 2.0 cm
Simple cyst	Not required
Suspicious cervical lymph node [§]	FNA node + FNA associated suspicious thyroid nodule(s) of any size

Suspicious feature: hypoechoic, microcalcification, infiltrative margins, tall than wide in transverse plane.

Low suspicious feature: isoechoic or hyperechoic solid, mixed solid-cystic, spongiform nodules.

* Aggregation of multiple microcystic components in more than 50% volume

§ Tg washout may be helpful in the diagnosis of lymph node metastasis

Ultrasound features of lymph nodes indicating high specificity (43-100%) of malignant involvement

Lymph node features

Microcalcifications
Cystic aspect
Peripheral vascularity
Hyperechogenicity
Round shape

《 Management guideline of differentiated thyroid cancer **Note4** 》

An active surveillance management can be considered as an alternative to immediate surgery in:

- Patients with very low risk tumors (e.g. papillary microcarcinomas or follicular variant of papillary carcinoma without clinically evident metastases or local invasion, with no convincing cytological or molecular (if performed) evidence of aggressive disease, not at a location adjacent to the trachea or on the dorsal surface of the lobe close to the recurrent laryngeal nerve, and with no signs of progression during follow-up

Initial Risk (of persistence/recurrence) Stratification System – 1 (Modified from 2015 ATA Guidelines)

- **Low Risk**

1. Papillary Thyroid Cancer with all of the following
 - (1) No local or distant metastases;
 - (2) All macroscopic tumor has been resected
 - (3) No tumor invasion of loco-regional tissues or structures
 - (4) The tumor does not have aggressive histology (e.g., tall cell, hobnail variant, columnar cell carcinoma, diffuse sclerosing variant)
 - (5) If 131I is given, there are no RAI avid metastatic foci outside the thyroid bed on the first post-treatment whole-body RAI scan
 - (6) No vascular invasion
 - (7) Clinical N0 or ≤ 5 pathologic N1 micrometastases (< 0.2 cm in largest dimension)*
2. Intrathyroidal, well differentiated follicular thyroid cancer with capsular invasion and no or minimal (< 4 foci) vascular invasion*
3. Intrathyroidal, papillary microcarcinoma, unifocal or multifocal, including V600E BRAF mutated (if known)*, without other worrisome features (e.g., aggressive histology, vascular invasion)
4. Intrathyroidal, papillary thyroid cancer, primary tumor 1-4 cm, V600E BRAF wild type, without other worrisome features (e.g., aggressive histology, vascular invasion)

《 Management guideline of differentiated thyroid cancer **Note5 continue** 》

Initial Risk (of persistence/recurrence) Stratification System – 2 (Modified from 2015 ATA Guidelines)

• **Intermediate Risk**

1. RAI avid metastatic foci in the neck on the first post-treatment whole-body RAI scan
2. Aggressive histology (e.g., tall cell, hobnail variant, columnar cell carcinoma, diffuse sclerosing variant)
3. Papillary thyroid cancer with vascular invasion
4. Clinical N1 or > 5 pathologic N1 with all involved lymph nodes < 3 cm in largest dimension*
5. Intrathyroid, papillary thyroid cancer, primary tumor 1-4 cm, V600E BRAF mutated (if known)*
6. Multifocal papillary microcarcinoma with extrathyroidal extension and V600E BRAF mutated (if known)*

• **High Risk**

1. Macroscopic invasion of tumor into the perithyroidal soft tissues (gross extrathyroidal extension),
2. Incomplete tumor resection
3. Distant metastases
4. Post-operative serum thyroglobulin suggestive of distant metastases
5. Pathologic N1 with any metastatic lymph node ≥ 3 cm in largest dimension*
6. Follicular thyroid cancer with extensive vascular invasion (> 4 foci of vascular invasion)

Therapeutic definition (ATA)

Definition of Treatment response	Assessment methods: TSH suppressive (oral administration of thyroxin) Stimulation: withdrawal thyroxin or rhTSH (Thyrogen) Serum Tg measurement or imaging diagnosis
Good response	No finding on imaging diagnosis and any of: 1. unstimulated: Tg <0.2ng/ml or 2. stimulated Tg <1 ng/ml
Biochemically incomplete response	No finding on imaging diagnosis and any of: unstimulated Tg >1ng/ml or stimulated Tg >10ng/ml
Structurally incomplete response	Structural or functional imaging has residual/remnant or metastatic lesion Regardless of Tg level, TgAb (+) or (-)
Undefined response	1. uncertain imaging finding (ultrasound, MRI/CT, PET) 2. indeterminate radioiodine uptake at thyroid bed 3. detectable unstimulated Tg but < 1 ng/ml or detectable stimulated Tg but < 10 ng/ml or TgAb(+) but stable or decline 4. any of the above and negative structural or functional imaging

《 Management guideline of differentiated thyroid cancer **Note7** 》

NCCN guidelines V.1 2016

PRINCIPLES OF THYROID-STIMULATING HORMONE (TSH) SUPPRESSION

- Because TSH is a trophic hormone that can stimulate the growth of cells derived from thyroid follicular epithelium, the use of levothyroxine to maintain low TSH levels is considered optimal in treatment of patients with papillary, follicular, or Hürthle cell carcinoma. However, data are lacking to permit precise specification of the appropriate serum levels of TSH.
- ▶ In general, patients with known structural residual carcinoma or at high risk for recurrence should have TSH levels maintained below 0.1 mU/L, whereas disease-free patients at low risk for recurrence should have TSH levels maintained either slightly below or slightly above the lower limit of the reference range.
- ▶ For low-risk patients with biochemical evidence but no structural evidence of disease (eg, Tg positive, but imaging negative), maintain TSH levels at 0.1–0.5 mU/L.
- ▶ Patients who remain disease free for several years can probably have their TSH levels maintained within the reference range.
- Given the potential toxicities associated with TSH-suppressive doses of levothyroxine—including cardiac tachyarrhythmias (especially in the elderly) and bone demineralization (particularly in post-menopausal women) as well as frank symptoms of thyrotoxicosis—the risk and benefit of TSH-suppressive therapy must be balanced for each individual patient.
- Patients whose TSH levels are chronically suppressed should be counseled to ensure adequate daily intake of calcium (1200 mg/d) and vitamin D (1000 units/d).

《 Reference 》

1. NCCN Clinical Practice Guidelines in Oncology: Thyroid Carcinoma Version 3. 2021.
2. Tuttle RM, Horris LF, Haugen BR, et al. Chapter 73 Thyroid-Differentiated and anaplastic carcinoma. In: AJCC Cancer staging manual. 8th edition. Springer, New York. 2017; pp 873-890.
3. 2015 American Thyroid Association Management Guidelines for Adult Patients with Thyroid Nodules and Differentiated Thyroid Cancer
4. Brito JP, Gionfriddo MR, Al NA, et al. The accuracy of thyroid nodule ultrasound to predict thyroid cancer: systemat review and meta-analysis. *J Clin Endocrinol Metab.* 2014;99:1253-1263.
5. Chen W, Parsons M, Torigian DA, et al. Evaluation of thyroid FDG uptake incidentally identified on FDG-PET/CT imaging. *Nucl Med Commun.* 2009;30:240-244.
6. Horvath E, Majlis S, Rossi R, et al. An ultrasonogram reporting system for thyroid nodules stratifying cancer risk for clinical management. *J Clin Endocrinol Metab.* 2009;94:1748-1751.
7. Ito Y, Amino N, Yokozawa T, et al. Ultrasonographic evaluation of thyroid nodules in 900 patients: comparison among ultrasonographic, cytological, and histological findings. *Thyroid.* 2007;17:1269-1276.
8. Kwak JY, Han KH, Yoon JH, et al. Thyroid imaging reporting and data system for US features of nodules: a step in establishing better stratification of cancer risk. *Radiology.* 2011;260:892-899.
9. NCCN Clinical Practice Guidelines in Oncology: Thyroid Carcinoma Version 2.2017.
10. Smith-Bindman R, Lebda P, Feldstein VA, et al. Risk of thyroid cancer based on thyroid ultrasound imaging characteristics: results of a population-based study. *JAMA Intern Med.* 2013;173:1788-1796.
11. Soelberg KK, Bonnema SJ, Brix TH, et al. Risk of malignancy in thyroid incidentalomas detected by 18F-fluorodeoxyglucose positron emission tomography: a systematic review. *Thyroid.* 2012;22:918-925.
12. Tae HJ, Lim DJ, Baek KH, et al. Diagnostic value of ultrasonography to distinguish between benign and malignant lesions in the management of thyroid nodules. *Thyroid.* 2007;17:461-466.

13. Takami H, Ito Y, Okamoto T, et al. Revisiting the guidelines issued by the Japanese Society of Thyroid Surgeons and Japan Association of Endocrine Surgeons: a gradual move towards consensus between Japanese and western practice in the management of thyroid carcinoma. *World J Surg.* 2014;38:2002-2010.
14. 2015 American Thyroid Association Management Guidelines for Adult Patients with Thyroid Nodules and Differentiated Thyroid Cancer.

